

Mechanical considerations for deep-bite correction with aligners



Neal D. Kravitz, Mazyar Moshiri, Jonathan Nicozisis, and Shawn Miller

Correction of deep-bite malocclusions with aligners is challenging for orthodontists. This review is intended to help orthodontists improve their clinical success in treating deep-bite malocclusions with aligners. Virtual case setup, attachment design, elastics, and bite ramp utilization are discussed in order to better equip orthodontists with a new “best practices” paradigm. (Semin Orthod 2020; 26:134–138) © 2020 The Authors. Published by Elsevier Inc. This is an open access article under the CC BY-NC-ND license. (<http://creativecommons.org/licenses/by-nc-nd/4.0/>)

Introduction

Correction of deep-bite malocclusions with aligners is biomechanically challenging for orthodontists. Specifically, research has shown that orthodontists struggle to achieve mandibular incisor intrusion, which remains one of the least accurate movements.¹⁻⁵ Unfortunately, the efficacy of deep-bite correction with aligners has not significantly improved despite advancements in technology.³⁻⁵ For these patients, the result is often prolonged aligner treatment with minimal overbite improvement.

There are a number of contributing factors, including, but not limited to: patient noncompliance, inefficient or improper virtual case setup, and loss of anchorage due to poor aligner retention. Although aligners have many advantages compared to braces for deep-bite malocclusions, such as occlusal protection and avoidance of broken brackets, their biomechanical disadvantages and challenges still need to be considered.

In this review, the aim is for orthodontists to improve their clinical success in treating deep-bite malocclusions with aligners. Virtual case setup, attachment design, elastics, and bite ramp

utilization will be discussed in order to better equip orthodontists with a new “best practices” paradigm.

Virtual case setup

A patient with a small lower arch perimeter or retrognathia is prone to the development of a deep-bite and a steep Curve of Spee. In these situations, the incisors supra-erupt until they contact opposing teeth or soft tissue and the mandibular second molars supra-erupt until they contact the maxillary second molars. Deep-bite correction usually requires a reversal of this process to flatten the Curve of Spee.⁶

A practical starting point for this reversal is to envision the final vertical positions of the upper incisors as they relate to the smile arc and then retro-engineer the other tooth movements accordingly. To preserve smile consonance and maxillary incisor display, the mandibular incisors and canines are primarily intruded.⁷ Therefore, teeth should be moved on the virtual treatment software to simulate the force vectors of a lower reverse Curve of Spee archwire (Fig. 1).

Such a prescription might read: “Intrude mandibular second molars 0.5 mm, extrude premolars and first molars 1.0 mm, intrude canines 1.5 mm, and intrude incisors 2.0 mm, to result in an open bite with heavy posterior contacts” (Fig. 2). Note that, the virtual treatment software is a visual representation of forces and not a predictor of final tooth positions, just as the shape of a reverse Curve of Spee archwire is not the desired occlusal plane.⁸

On occasion, the mandibular posterior teeth also will be excessively linguo-inclined,

Private practice in South Riding, 25055 Riding Plaza, Suite 110, South Riding, VA 20152, United States; Invisalign Master Faculty and private practice in St. Louis, MO, United States; Invisalign Master Faculty and private practice in Princeton, NJ, United States; Private practice in Orange, CA, United States.

Corresponding author. E-mail: nealkravitz@gmail.com

© 2020 The Authors. Published by Elsevier Inc. This is an open access article under the CC BY-NC-ND license.

(<http://creativecommons.org/licenses/by-nc-nd/4.0/>)

1073-8746/12/1801-\$30.00/0

<https://doi.org/10.1053/j.sodo.2020.06.010>

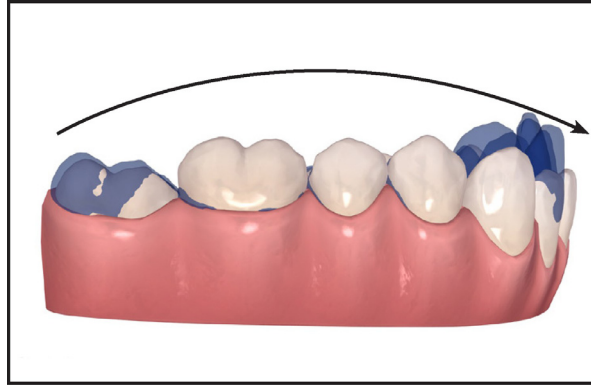


Fig. 1. Mandibular reverse Curve of Spee mechanics. The flatter the mandibular plane, the more over-engineering of the virtual case setup needs to be performed. This is particular true of cases where space closure or IPR is occurring. (The attachments have been removed for clarity.).

resulting in a steep Curve of Wilson. This inclination is best viewed by turning the digital model around to the back. If this occurs, prescribing 5° of buccal crown tip to the mandibular premolars and molars will flatten the Curve of Wilson and create a “resultant” extrusion that will contribute to deep-bite correction.

Resultant (relative) versus absolute movements

Resultant (also referred to as “relative”) intrusion or extrusion differs from absolute intrusion or extrusion in the vertical plane. These resultant movements incorporate predictable buccal and lingual crown tip movements to achieve vertical changes. Buccal and lingual crown tip is the most accurate movement with Invisalign,¹ likely because the aligner material primarily flexes in a buccal-lingual direction.

Labial crown tip of the incisors produces a resultant intrusion for bite opening and lingual crown tip of the incisors produces a resultant extrusion for bite deepening.^{1,8} As such,

interproximal reduction should be used judiciously in deep-bite cases, and always be incorporated with incisor intrusion.⁸ Likewise, deep-bite malocclusions with preexisting mandibular spacing are particularly challenging. These cases may benefit from significant over-engineering or a hybrid technique of upper aligners with lower fixed appliances.

For the most part, two types of resultant tooth movements should be considered as aiding in deep-bite correction: 1) the resultant extrusion of the mandibular posterior teeth via buccal crown tip, which will flatten the Curve of Wilson, and 2) the resultant intrusion of the mandibular incisors via labial crown tip, which will flatten the Curve of Spee. Glaser refers to these movements as predictable “free rides” that often do not require any specific attachments (Fig. 3).⁸

Attachments

Attachments minimize aligner lift-off and loss of retentiveness, serving as anchorage for described

Please place:

1. G5/G7 attachments as large as possible on L4-6,
2. HBAs, 4 mm x 1.25 mm, beveled to the gingival on L3s,
3. Intrude L7s: 0.5 mm; Extrude L456s: 1.0 mm; Intrude L3s: 1.5 mm; Intrude L2112: 2.0 mm,
4. Finish with a 0.5-1.0 mm openbite.

Show extrusion of the posterior segment and intrusion of the anterior segment to over-engineer leveling and correction of the deep bite, finishing with heavy posterior contacts and zero Centric contacts mesial 3-3.

Fig. 2. A sample Special Instructions in ClinCheck for a deep-bite patient. This recommendation may need to be exaggerated in patients who are non-growing, brachycephalic, or where space closure is needed. The selection of bite ramps comes earlier in the prescription form.

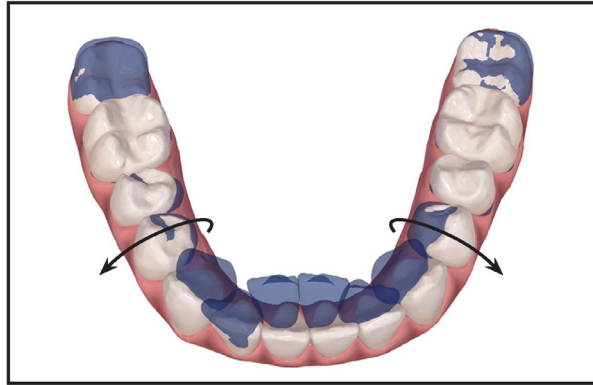


Fig. 3. An occlusal view showing the resultant intrusion of the mandibular incisors and the resultant extrusion of the mandibular premolars to assist in bite opening. Proclining the incisors also increases the surface area on the cingula, which aids intrusion. (The attachments have been removed for clarity.)

movements. For lower reverse Curve of Spee mechanics, attachments should be placed on the extruding mandibular teeth. Attachments are often unnecessary for teeth undergoing intrusion, with the exception of the mandibular canines if more than 1 mm mandibular incisor intrusion is needed.

Dome-shaped, fifth-generation (G5) and seventh-generation (G7) attachments, which are specific for Invisalign, can be placed on the posterior teeth. G5s are designated for the premolars and G7s are designated for the molars, but there is no difference in design (Fig. 4). If conditions are not met for these attachments or a different aligner system is used, then horizontal beveled attachments (HBA) can be used. HBAs are also the preferred attachment for the mandibular canines.

The orthodontist should request that HBAs are 4 mm wide and 1.25 mm thick, angulated gingivally into the crown without a ledge. Orienting

the beveled surface of the attachment gingivally directs the pushing vector perpendicularly against the lingually-inclined crown. It also eliminates the attachment's gingival undercut to minimize the chance of debonding. This gingival-orientation step can be written as a default in the Clinical Preferences section or performed manually on the virtual treatment software.

For Invisalign, G5/G7s or HBAs need to be prescribed in the ClinCheck instructions because anchorage for deep-bite correction is one of the lowest priorities of the software. Therefore, if teeth have root tip or rotations greater than 5°, the software will place smaller, optimized attachments to primarily address those issues instead. These optimized attachments are less than ideal for deep-bite correction as they do not provide the necessary anchorage.⁹

Root tip or rotation therefore may need to be addressed during refinement, after significant

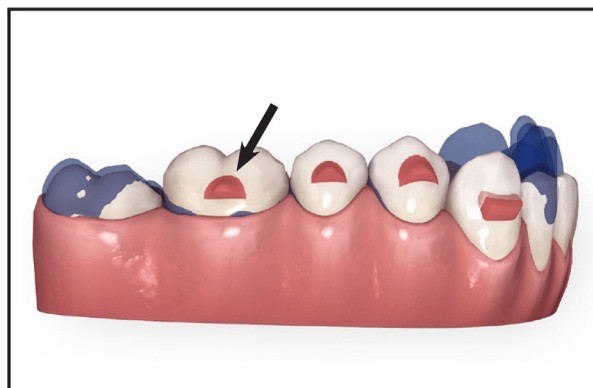


Fig. 4. Invisalign's dome-shaped G5 attachments on the premolars and G7 attachments on the first molars. These attachments may not be possible in younger patients with shorter clinical crowns. The canine receives an HBA.

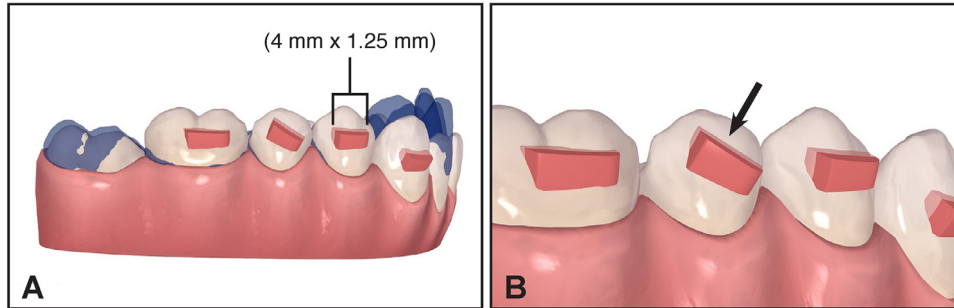


Fig. 5. A. HBAs (4 mm wide; 1.25 mm thick) oriented gingivally without a ledge. B. A diagonal or sash HBA on the mandibular right second premolar for simultaneous rotation and extrusion.

deep-bite correction has been achieved. Alternatively, an HBA can be rotated diagonally across the crown in a ‘sash’ orientation.¹⁰ This enables the pushing vectors to simultaneously effect root tip and rotation, while extruding the premolars or supporting the intrusion of the anterior teeth (Figs. 5A and B).

Generally, it is advantageous to set the Clinical Preferences to use the largest attachment possible. Posterior and mandibular anterior attachments should be moved as incisal or coronal as possible where the aligner force levels are strongest, without interfering with occlusion. However, attachment shape and location may vary depending on the use of supporting auxiliaries, such as elastics and bite ramps.

Supporting auxiliaries

Class II elastics and bite ramps support the mechanics for deep-bite correction. Elastics assist in mandibular molar extrusion (when programmed into the virtual treatment plan) and mandibular incisor proclination; therefore, they can be utilized even for Class I patients. Bite ramps are helpful in intruding the mandibular anterior teeth and disarticulating the posterior teeth to allow for their extrusion. They are commonly utilized in brachycephalic patients.

Class II elastics are often connected from hooks in the aligners over the maxillary canines to buttons on the mandibular first molars. Buttons are preferable on the molars because the elastic pulls directly on the teeth. If maxillary canine intrusion or anchorage is needed, the hooks should be moved to over the first premolars as not to counteract the aligner’s anterior intrusive forces. This may necessitate moving the buttons back to the mandibular second molars.

Bite ramps are commonly located on the lingual surfaces of the four maxillary incisors. If maxillary anterior intrusion is desired, as is often the case in Class II Division 2 malocclusions, the bite ramps should be moved to the canines instead. This is because bite ramps reduce the pressure directed along the long-axes of the maxillary incisors needing intrusion. Bite ramps cause less plastic to be in contact with the incisors’ cingula, which reduces the surface area available for the desired intrusion force vectors. For the same reason, bite ramps also limit torque expression (Fig. 6).

Conclusion

To improve the efficacy of deep-bite correction with aligners, orthodontists should prescribe reverse Curve of Spee mechanics: specifically, extrusion of the posterior teeth and intrusion of

USAGE OF MAXILLARY INCISOR BITE RAMPS

| Indications | Contraindications |
|---------------------------------------|----------------------------------|
| Hypodivergent | Hyperdivergent (growing patient) |
| Posterior extrusion | Maxillary incisor intrusion |
| Mandibular en-masse incisor intrusion | Maxillary incisor torque |

Fig. 6. Usage of maxillary incisor bite ramps.

the anterior teeth, resulting in an overcorrection to a simulated anterior open bite. Invisalign's G5/G7s or HBAs should be placed on teeth undergoing extrusive forces, and Class II elastics and bite ramps can be added for support. Above all, the virtual treatment software should be used as a visual representation of forces rather than a predictor of final tooth position.

References

1. Kravitz ND, Kusnoto B, BeGole E, Obrez A, Agran B. How well does invisalign work? A prospective clinical study evaluating the efficacy of tooth movement with Invisalign. *Am J Orthod Dentofacial Orthop.* 2009;135:27–35.
2. Krieger E, Seiferth J, Marinello I, et al. Invisalign treatment in the anterior region: were the predicted tooth movements achieved? *J Orofac Orthop.* 2012;73:365–376.
3. Khosravi R, Cohanin B, Hujuel P, et al. Management of overbite with the Invisalign appliance. *Am J Orthod Dentofacial Orthop.* 2017;151:691–699.
4. Grünheid T, Loh C, Larson BE. How accurate is Invisalign in nonextraction cases? Are predicted tooth positions achieved? *Angle Orthod.* 2017;87:809–815.
5. Charalampakis O, Iliadi A, Ueno H, Oliver DR, Kim KB. Accuracy of clear aligners: a retrospective study of patients who needed refinement. *Am J Orthod Dentofacial Orthop.* 2018;154:47–54.
6. Kravitz N, Jorgensen G, Frey S, Cope J. Resin bite turbos. *J Clin Orthod.* 2018;2:456–461.
7. Hamdan AM, Lewis SM, Kelleher KE, Elhady SN, Lindauer SJ. Does overbite reduction affect smile esthetics? *Angle Orthod.* 2019;89:847–854.
8. Glaser BJ. *Insider's Guide to Invisalign treatment: a Step-by-Step Guide to Assist You With Your ClinCheck treatment Plans.* 1st ed. Sacramento: Publishing; 2017.
9. Glaser Dr. BJ. Glaser's 10 commandments of attachment design: ten simple rules to keep your patient's invisalign treatment on track. *Orthodontic Products.* 2016:30–35.
10. Nicozisis J. Attachment beauty queen: the "sash" for rotation correction of upper lateral incisors. *J Clin Orthod.* 2016;50:189–190.