



# Incognito™ Appliance System Treatment Utilizing Orthognathic Surgical Correction

by Dr. Shawn Miller



Dr. Shawn L. Miller is in private practice in Orange, CA and Aliso Viejo, CA. He lectures locally on PAOO,

Incognito™ Appliance System and Interdisciplinary Orthodontic Treatment. He is Board Certified by the American Board of Orthodontics, Incognito System Certified and Wilckodontics Certified.

For malocclusions with significant skeletal disproportions and/or asymmetries, often Orthognathic Surgical correction is the only treatment modality able to get ideal aesthetic and functional correction. Despite advances in skeletally-based anchorage (such as bone plates and temporary anchorage devices), and dentoalveolar surgical techniques (such as Periodontally Accelerated Osteogenic Orthodontics), there is still an important place for traditional Orthognathic Surgery in a modern orthodontic practice.

With the Incognito™ Appliance System, once a certain level of comfort and proficiency is attained with simpler malocclusions, there should be little issue transitioning into more complex cases. Impacted canines, premolar extractions, and skeletal discrepancies are some examples of more challenging cases to treat. All of these cases can be successfully treated with the Incognito System.

Many patients seeking Orthognathic Surgical correction are looking for functional improvement in terms of speech, mastication, temporomandibular joint and muscle disorders, and perhaps Obstructive Sleep Apnea. Just as critically, these patients are often also seeking cosmetic improvement. Common concerns we see are with the facial profile, in regards to a retruded chin, prognathic mandible or underdeveloped midface. In the frontal plane, some aesthetic complaints are skeletal asymmetries, canted occlusions, and deficient/excessive vertical maxillary position. Since these patients are already deeply concerned about their appearance, often having visible braces is not an acceptable option. For these patients we recommend the Incognito Appliance System.

The Incognito System is a wonderful appliance offering unparalleled aesthetic benefits, and due to the customization of the appliance, a very precise pre-surgical setup. Having the case setup prior to beginning treatment allows the orthodontist and surgeon to make any desired alterations before even starting care. It also allows for the treatment to be more efficient and progress sequentially without unintentional deviation.

Although 'aligner therapy' offers some of the same advantages, it has some significant disadvantages. Despite everyone's best efforts, surgical cases very rarely come back with 'perfect occlusions' after stent removal and healing. There are usually fairly considerable changes that need to be made to individual tooth positions, interarch relationships and sometimes arch form (if multiple piece LeFort surgery). With aligners, these changes are quite difficult to make chairside and often require new impressions and fabrication of new aligners. This either delays treatment at best, or at worst, the aligners are not able to make the correction adequately due to insufficient forces (commonly with arch expansion or posterior torque control).

We will present two Class III asymmetry cases treated with the Incognito System. One is dual arch Incognito system treatment, and one is a hybrid case with Incognito appliances on the maxillary arch and traditional labial braces on the mandibular arch.

## Daniel

Daniel has been a patient in our practice for many years – he was first seen as a young boy when his Class III skeletal growth pattern was quite apparent. After monitoring his growth for a number of years, it was determined that mandibular growth was complete and he was ready for treatment at age 18. He was quite emotionally prepared for orthognathic surgery, but since he was just starting college, he did not want traditional braces. He was thrilled to have the Incognito System as a treatment option.

Our diagnostic concerns were his Class III malocclusion (more severe on right), dental midline discrepancy, anterior open bite, negative overjet, and mandibular crowding. Skeletally, he showed midface deficiency (Figure 1A). Although he may have been treated with mandibular extractions and substantial dental compensations, we strongly felt that surgical correction would give us better aesthetics and function.

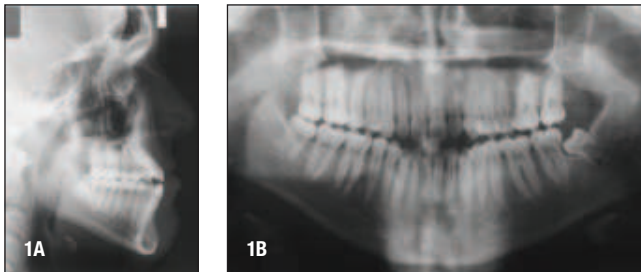


Figure 1A-B

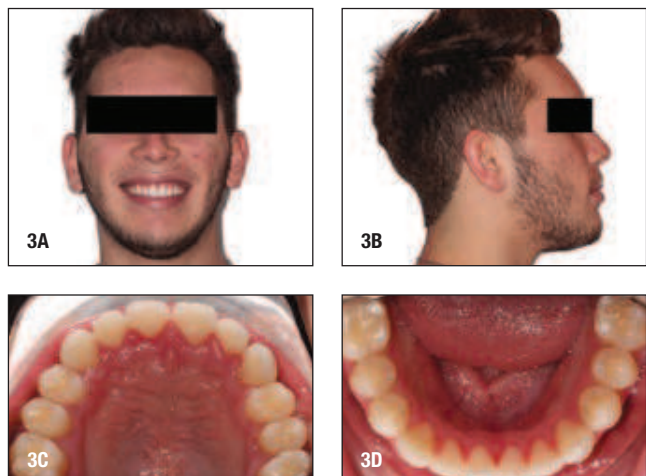
After third molar removal (Figure 1B), Daniel's case was submitted to 3M Unitek and the surgical setup was fabricated and approved. He was bracketed (Figure 2A-F) and after uneventfully progressing through our wire sequencing into 16×24 SS surgical wires, Daniel was ready for surgery at eight months. One week prior to surgery, some labial buttons were placed on the lower arch, and partial maxillary braces with a 16×22 SS labial archwire were placed on the upper arch at the request of the surgeon to aid in fixation.

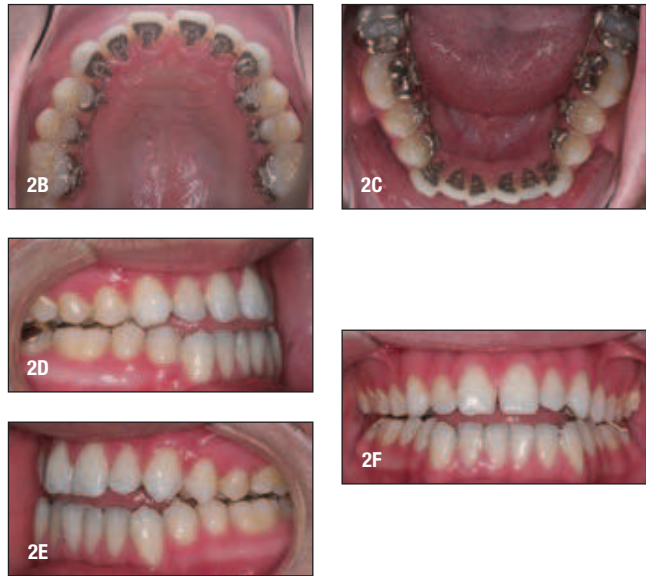
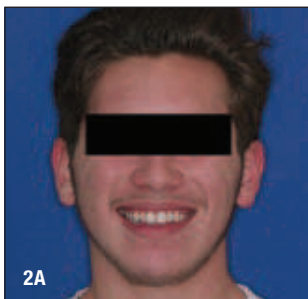
Figure 2A-F: Bonding appointment.

Since the maxilla was to be done in three-pieces, the maxillary lingual wire was removed. The surgery consisted of advancing, slightly intruding and rotating the maxilla with a LeFort I three-piece osteotomy. An orthotic stabilizing appliance was used to unload the stresses on the TMJ. After a period of healing, the surgical stent was removed, as well as the labial buttons/braces and orthodontic treatment could commence. Finishing 18×18 TMA wires and a combination of vertical and Class III elastics were utilized to complete Daniel's case.

Unfortunately after surgery, Daniel's compliance with appointments and elastics was poor (at one point he was absent for 3.5 months). As a result, finishing took longer than expected, as he was completed 11 months after surgery (Figure 3A-I). Total treatment time was 19 months. Restoratively the maxillary right canine had the cusp tip bonded for functional guidance, since it was worn off prior to treatment. He was retained with vacuformed retainers with instructions for nighttime wear.



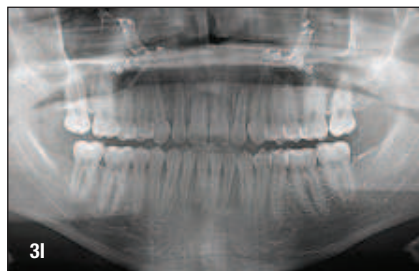
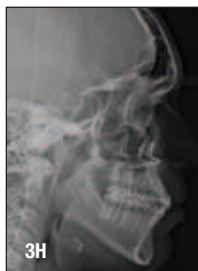
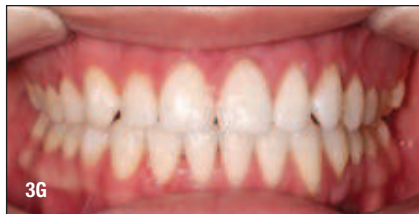
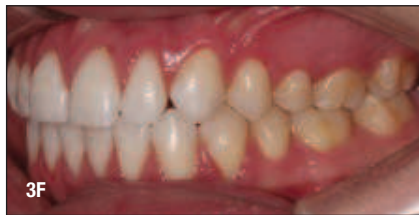
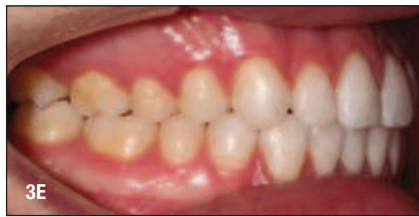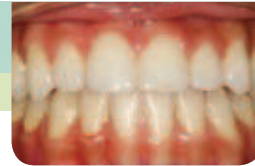Figure 3A-I: End of treatment.

## Steve

Steve came to us as a 19-year-old university student, with a chief complaint of a poor occlusion and noticeable facial asymmetry. Since he was a freshman in college, appearance was a major concern, so he elected to have maxillary Incognito™ Appliance System treatment for aesthetics. To help mitigate costs, and because he didn't show much of his mandibular dentition when smiling or speaking, we elected to do traditional labial metal brackets on the lower arch with Victory Series™ APC™ II Adhesive Coated Braces.

Our diagnostic workup for Steve consisted of mounted centric models, a CBCT Scan and clinical photographs (Figure 4A-K). Our diagnosis was a Class III skeletal and dental malocclusion (more severe on the left), maxillary and mandibular asymmetry (to his right), and occlusal cant. He also had mild mandibular crowding, dental midline discrepancy, inadequate overbite and overjet, as well as incongruent arch forms. Due to the nature and extent of the skeletal asymmetry, it was decided that Orthognathic Surgery would be the most ideal treatment option.

The case was submitted to 3M Unitek for setup and approval. Both arches were set up, however, only Incognito braces were fabricated for the upper arch at the patient's request. Once receiving his case back, both arches were bonded on the same day. Normal archwire progression was done as we worked up to stainless steel archwires. Using the lower setup model as a guide, our lower steel archwires were formed to match the surgical setup of the final case.

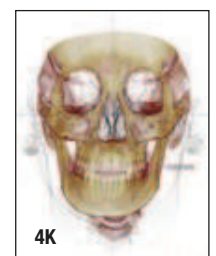
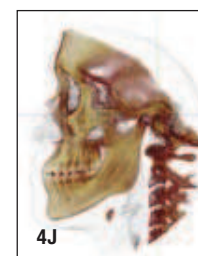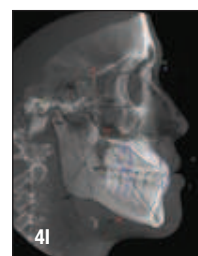
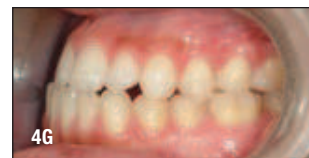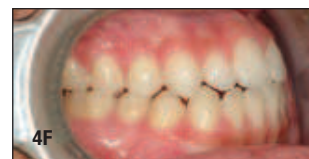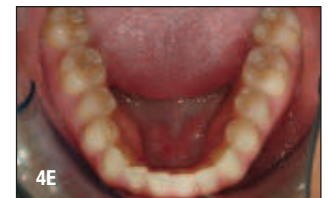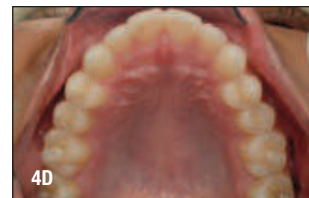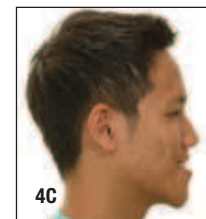
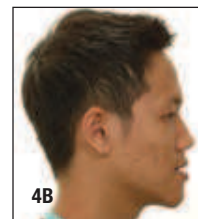


Figure 4A-K: Beginning of treatment.



Steve was ready for surgery eight months into treatment. One week prior to surgery, some buccal buttons were placed on the maxillary arch at the request of the surgeon to aid in fixation. The surgery consisted of a maxillary LeFort I osteotomy with leveling (intrusion on the left side) and rotation to the midline, a mandibular sagittal split osteotomy on the right and mandibular vertical oblique osteotomy on the left side. An orthotic stabilizing appliance was used to unload the stresses on the TMJ. After adequate healing, there was removal of the stent appliance and buttons, and finishing 17×25 TMA wires were used in both arches (Figure 5A-E). Finishing bends and elastics were used to complete the case.

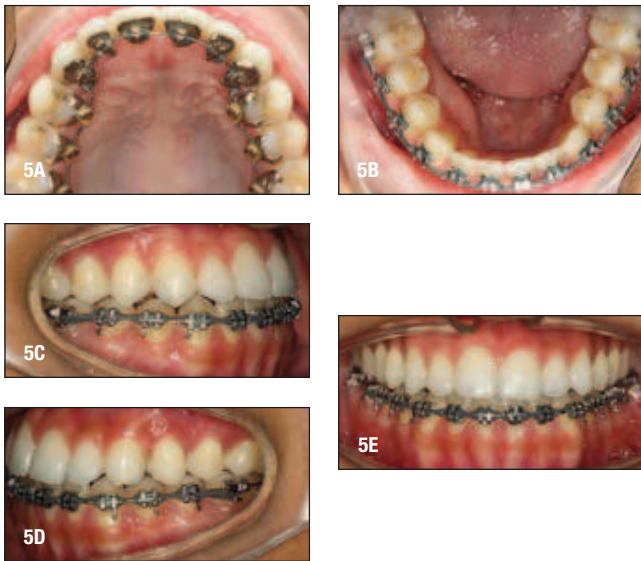


Figure 5A-E: Finishing.

The total treatment time was 13.5 months (Figure 6A-G) and he was retained with vacuformed retainers.

Steve is ecstatic about his final results, and the entire process. For him, the Incognito™ Appliance System was extremely important in his decision to move ahead with treatment. Interestingly, after going through this process, he is even thinking about a future career as an Oral Surgeon.

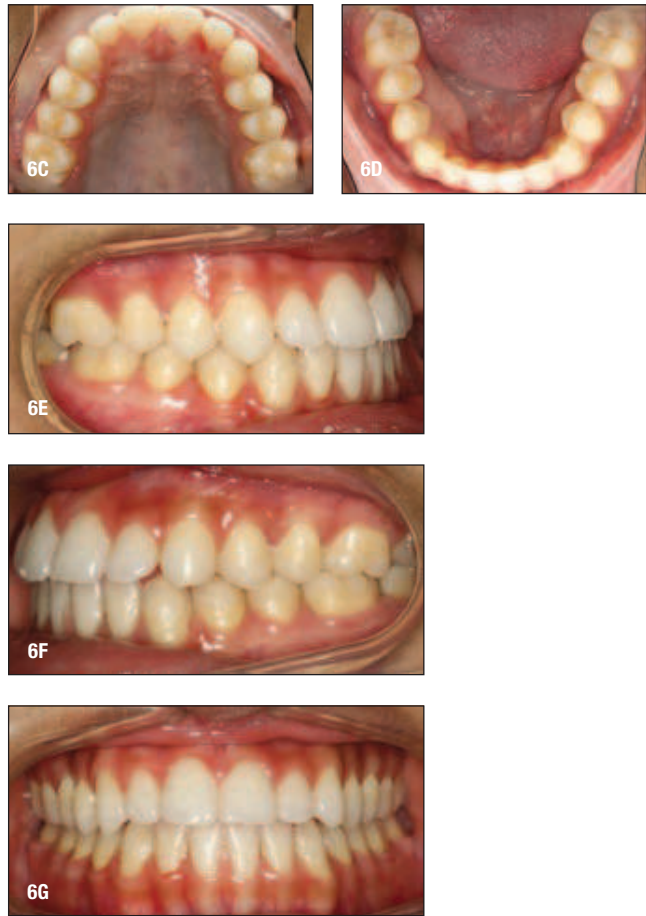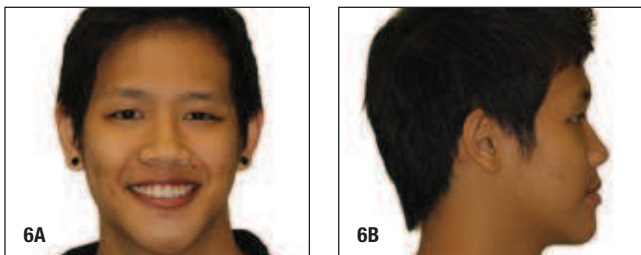


Figure 6A-G: End of treatment.

## Conclusion

These two cases are wonderful examples of successfully using the Incognito Appliance System utilizing Orthognathic Surgery as an important treatment modality. Beyond traditional orthodontic cases, we have been effective in using Incognito with more challenging cases such as those involving Periodontally Assisted Osteogenic Orthodontics (PAOO) or Orthognathic Surgery. Treatment times have been very comparable, if not better than with traditional braces, in part due to the precision in the setup and bracket/wire customization. If any of our patients are interested in truly invisible treatment, yet have surgical needs, we are confident in recommending the Incognito Appliance System.

## Acknowledgements

Charles Hasse, DDS, MD. Oral and Maxillofacial Surgeon, Private Practice, Irvine, CA.

Case photos provided by Dr. Shawn Miller.

